Diagnostic and Interventional Imaging 102 (2021) 273–278

Solicited review/*Interventional imaging*

Percutaneous cryoanalgesia for pain palliation: Current status and future trends

Dimitrios Filippiadis[a,*], E. Efthymiou[a], A. Tsochatzis[a], A. Kelekis[a], J.D. Prologo[b]

[a] *Second Radiology Department, University General Hospital "ATTIKON", Medical School, National and Kapodistrian University of Athens, Athens, Greece*
[b] *Department of Radiology and Imaging Sciences, Emory University School of Medicine, 1364, Clifton road NE, 30322 Atlanta, GA, USA*

ARTICLE INFO

Keywords:
Pain management
Neural conduction
Cryoanalgesia
Neuralgia

ABSTRACT

Cryoanalgesia, otherwise termed cryoneurolysis, refers to application of extreme cold upon peripheral nerves for palliation of pain associated to nerve lesions or biomechanical syndromes of neoplastic and non-neoplastic substrate. Application of cryoanalgesia initiates a cascade of pathophysiologic events interrupting nerve conduction of painful stimuli without irreversible nerve damage. Cryoanalgesia is considered a safe procedure with minimal risk of complications when performed with percutaneous approaches under imaging guidance. In the era of an opioid overdose crisis, cryoanalgesia can be proposed as an alternative aiming at controlling pain and improving life quality. Imaging guidance has substituted open surgical and nerve stimulation approaches in nerve identification, significantly contributing to the minimally invasive character of percutaneous approaches. Ultrasound or computed tomography can serve as low cost, ideal guiding techniques due to their abilities for precise anatomic delineation, high spatial resolution and good tissue contrast. The purpose of this review is to become familiar with the most common imaging guided percutaneous cryoanalgesia indications, to learn about different technical considerations during performance providing the current evidence. Controversies concerning products will be addressed.

© 2020 Société française de radiologie. Published by Elsevier Masson SAS. All rights reserved.

1. Introduction

Percutaneous cryoablation leads a continuously expanding role in interventional radiology therapeutic armamentarium [1,2]. As the Western societies battle against established or upcoming opioid epidemic crisis, interventional radiology techniques for pain reduction constitute attractive therapeutic alternatives characterized by lack of drug usage. Percutaneous therapies used for neurolysis include application of chemical agents, such as alcohol or phenol and thermal techniques, such as radiofrequency, microwaves and cryoablation [3,4].

Cryoanalgesia is a term describing application of extremely cold temperatures to peripheral nerves aiming to pain palliation. Cryoanalgesia (otherwise termed cryoneurolysis) has initially been used intraoperatively under direct visualization of nerves after surgical exposure; literature evidence of surgical approaches in terms of mainly retrospective and few prospective studies reported favorable results over other pain control methods [4–11]. With the evolution of imaging and interventional radiology, percutaneous cryoanalgesia can be applied to treat pain related to different neoplastic and non-neoplastic diseases without the need of guidance by palpation landmarks or nerve stimulation, since imaging guidance can be effectively used for this purpose [12]. By using imaging guidance, even deep nervous system structures can be safely and effectively reached by means of percutaneous approaches whilst at the same time, the ablative effect upon target zones can be documented and monitored.

The purpose of this review is to make the reader more familiar with the most common imaging-guided percutaneous cryoanalgesia indications, to learn about different technical considerations during performance providing the current evidence. Controversies concerning products will be addressed.

2. Pathophysiology

In cryoanaglesia, a cryoprobe is used to reversibly ablate and provide analgesia in peripheral nerves by the application of extremely cold temperatures. The cryoprobe consists of a hollow tube with a smaller inner and a larger outer tube; gas in high pressure travels from the proximal inner tube to its distal part where it passes through a very narrow aperture into the larger outer tube (which is at a low pressure state) where it rapidly expands within the distal tip [13]. This leads to heat extraction from the tip of the

Abbreviations: °C, Celcius; CT, Computed tomography; 3D, 3 dimensional.

* Corresponding author.
E-mail address: dfilippiadis@yahoo.gr (D. Filippiadis).

https://doi.org/10.1016/j.diii.2020.11.007
2211-5684/© 2020 Société française de radiologie. Published by Elsevier Masson SAS. All rights reserved.

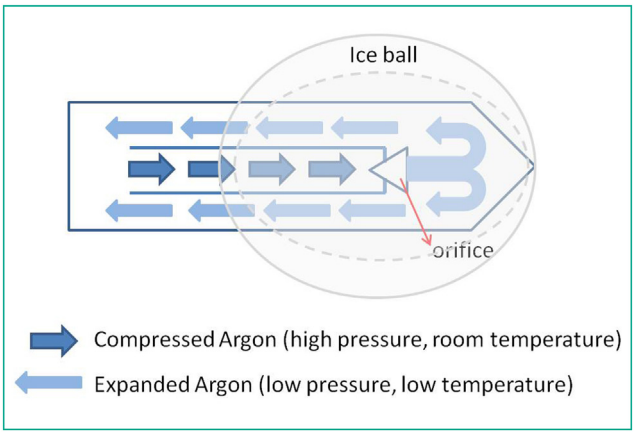

Fig. 1. Joule Thomson effect in cryoablation: a gas tank supplies Argon to the dual chambered cryoprobe through a pressure regulator. At the end of the inner chamber Argon gas passes through an orifice and expands, cooling down and absorbing thermal energy from the surrounding tissues. The Argon gas is directed backwards through the outer chamber and is eventually released in the atmosphere. Ice ball long axis depends upon the length of the un-insulated tip of the cryoprobe whilst its short axis depends upon flow rate of Argon gas.

probe due to Joule–Thomson effect resulting in drop of temperature even below −170 °C (if using Argon gas) and formation of an ice ball at the tip of the cryoprobe (Fig. 1) [13]. The cold gas is vented back through the outer tube to a ventilated outlet so no gas inserts into the patient's tissues [13]. Other gas or liquid may be used, such as nitrogen or CO_2 without using the Joule–Thomson effect.

The application of cold disrupts the nerve structure with loss of axonal continuity, leaving the myelin sheath and the endoneurium intact (Sunderland 2 injury) (Fig. 2) [14]. This neural injury results in conduction block, Wallerian degeneration and predictable axonal regeneration over time (upon an intact connective tissue scaffold) along the ablated neural structures with restoration of the nerve function and without the risk of neuroma formation [13,15]. Freezing of the target nerve branches results in conduction cessation of pain-related impulses. The intensity and duration of the analgesic effect depends on the degree of damage from the ice ball and is usually measured in weeks or months [16,17].

3. Products and ablation protocols

There are two different types of products available in the market at the moment for percutaneous cryoanalgesia. Choice lies between cryoprobes (cryoneedles) used for tumor ablation or those specifically designed for nerve analgesia. The former range from 8- to 17-Gauge in diameter; some of them utilize argon for ice ball formation through the Joule–Thomson effect, whilst others are liquid Nitrogen systems with no application of Joule–Thomson effect. Although the generator can support simultaneous use of multiple cryoprobes, it lacks a build-in neurostimulator for motor and sensory testing. On the other hand, cryoprobes for nerve analgesia range from 14- to 24-Gauge in diameter and utilize carbon dioxide or nitrous oxide for ice ball formation; the available generators have built-in nerve stimulators in order to perform test for assessing sensory and motor responses aiming at achieving proper localization of the target neural structure prior to cryoanalgesia [13,17]. Single or double alternating freeze–thaw cycles ranging from 3 to 10 minutes and from 3 to 5 minutes, respectively are applied; temperatures below −40° are avoided with shorter duration of the freezing cycle [13,18,19]. Cryoprobes used for tumor ablation can be directly inserted without the need for trocars unless approach is associated to passing through osseous cortex. An introducer, commonly a large gauge intravenous catheter or a needle, can be used to facilitate probe insertion and infiltration with local anesthetic [13].

4. Technique

Cryoanalgesia is usually performed with the use of local anesthesia or conscious sedation, although some sessions especially in cancer patients may be painful requiring general anesthesia; careful preoperative evaluation is needed to adapt sedation level to the patient. Decreasing power setting and time of application may be an option to decrease the pain at the early phase of treatment. Cryoablation probes are placed under imaging guidance in the target region so the predicted ablation zone will include the neural structure of interest [20,21]. Prior to cryoablation, critical diagnostic information can be obtained by injection of a local anesthetic such that the therapeutic goal can be precisely defined; cryoanalgesia for pain palliation should be performed when block test is positive [18]. Cryoanalgesia may be performed as an incremental strategy after recurrence of symptoms post-infiltration or chemical neurolysis with ethanol or phenol; however, in many centers, cryoanalgesia constitutes the first choice post a positive diagnostic block or infiltration due to the technique's high targeting (visible ice ball) and the reduced chance of post-treatment neuroma formation. Informed consent after discussion regarding procedure's risks, complications and contraindications is mandatory and should be obtained prior to the procedure in all patients [13]. Extended room and local sterility measures are a prerequisite; although prophylactic antibiotics are not necessary, practice differs throughout the globe. Imaging guidance techniques include ultrasound, fluoroscopy (with or without cone beam CT with live three-dimensional [3D] needle guidance algorithms) and computed tomography. Although magnetic resonance imaging can provide improved visualization of the nerve, real-time guidance without ionizing radiation, it is not yet widely available in the vast majority of the centers mostly due to duration, availability and cost issues. On the other hand, 3D navigation and/or fusion imaging systems provide augmented precision of needle placement and can easily be incorporated in the existing workflow resulting in augmented precision of needle placement [22,23]. Contraindications to percutaneous cryoanalgesia include inability to consent, anatomy-related issues precluding safe access to region of interest, bleeding disorders, coagulopathy, infection, cold urticaria, cryoglobulinemia and Raynaud's syndrome [12,15].

5. Clinical applications

Literature data support application of cryoanalgesia for pain management in a variety of neuralgias and conditions with favorable results [15–20,24–53]. Percutaneous cryoanalgesia has been reported in the settings of intractable pain related to abdominal, pelvic and thoracic neoplasms (Fig. 3, Fig. 4), to benign substrate such as occipital neuralgia, post-amputation limb pain, postoperative pain syndromes, knee osteoarthritis or post-total arthroplasty pain, inguinodynia, chronic orchialgia, pain related to burns, post-herpetic neuralgia, pudendal neuralgia, acute pain related to tissue injury, pain secondary to neuromas and nerve sheath tumors and various peripheral neuralgias (Fig. 5), as well as to biomechanical syndromes, including lumbar and cervical facet joints osteoarthritis [15,17–20,24–56].

The effectiveness of percutaneous cryoanalgesia ranges from partial to complete symptomatic relief with variable duration as the targeted sensory nerve will regenerate and thus regain function [20]. In most studies, maximal symptomatic relief lasts for one month after treatment and gradual loss of effectiveness over

Fig. 2. Schematic representation of Sunderland classification for nerve injury: I: Focal conduction block in the axon without any Wallerian degeneration. II: Disruption of the axon. III: Disruption of the axon and endoneurium. IV: Disruption of the axon, endoneurium and perineurium. V: Disruption of the total nerve.

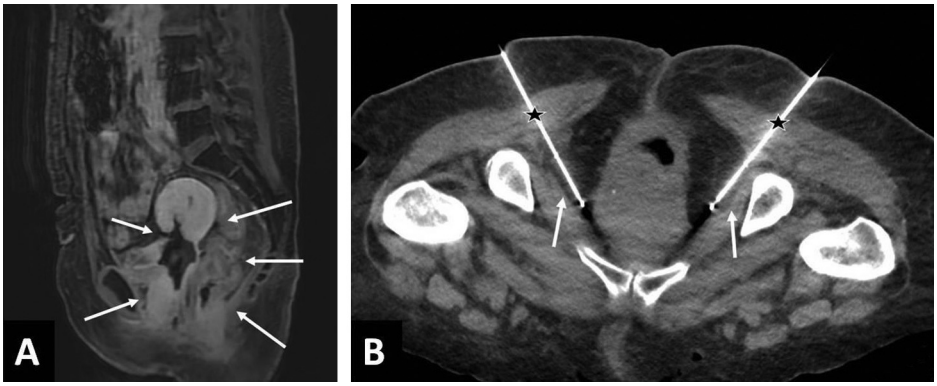

Fig. 3. 48-year-old woman with intractable pain related to a cervical mass and rectovaginal fistula. A. Fat-suppressed T1-weighted MR image in the sagittal plane obtained after intravenous administration of a gadolinium chelate shows cervical mass and rectovaginal fistula (arrows). B. Intraprocedural CT image obtained in the axial plane during palliative bilateral pudendal nerve cryoablation demonstrates cryoablation probes (stars) targeting the pudendal canal (arrows).

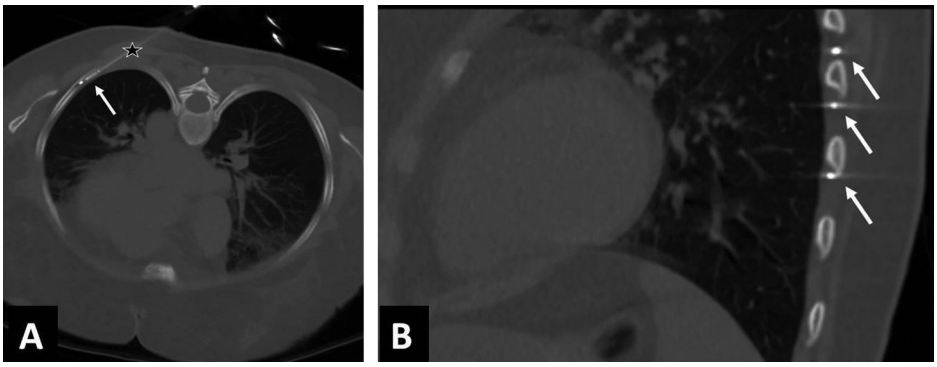

Fig. 4. 40-year-old woman with intractable neuropathic pain related to previous radiation to thoracic rib metastases. A. Intraprocedural CT image obtained in the axial plane demonstrates placement of the cryoablation probe (star) in the intercostal space (arrow). B. Intraprocedural CT image obtained in the sagittal plane shows three cryoablation probes placed in the intercostal spaces (arrows) corresponding to patient's pain.

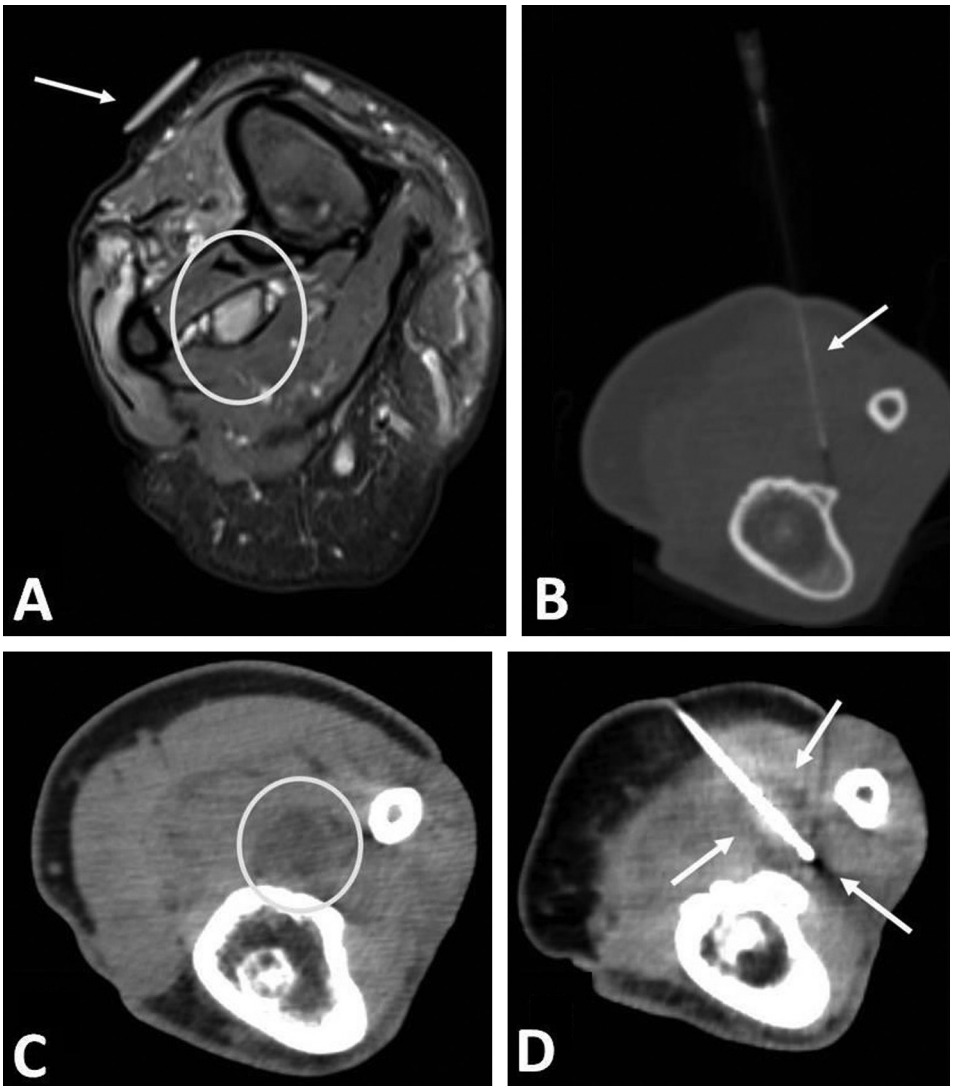

Fig. 5. 58-year-old man with intractable residual limb pain related to in a below the knee amputation. A. Proton density-weighted MR image in the axial plane at the level of the tibia-fibula demonstrates hyperintense neuroma (circle). Surface marker (arrow) was placed by the patient to indicate the epicenter of his discomfort. B. Intraprocedural CT image obtained in the axial plane during diagnostic injection. A 22-Gauge spinal needle (arrow) is used to deliver Bupivacaine to the suspected pain generator. C. Intraprocedural CT image obtained in the axial plane after intravenous administration of iodinated contrast material demonstrates the injected mixture surrounding the neuroma (circle). D. Intraprocedural CT image obtained in the axial plane shows the cryoprobe at the neuroma level and the ice covering the lesion (arrows).

the following months. Patients may undergo repeated treatments as necessary without increasing risks, as it is a safe procedure. Data from prospective studies show favorable results (50–60% of patients with significant pain reduction) for 6–12 months [6,30,37,38,43,49,56]. There is only one randomized control trial evaluating the efficacy and safety of cryoanaglesia, which has shown symptomatic relief for up to 150 days and more randomized control trials are necessary to further assess the efficacy and benefit-to-risk ratio of the technique in different clinical scenarios providing valuable information which can also be used for equipment optimization [36].

As far as malignant substrate and cryoanalgesia are concerned, Prologo et al. have applied CT-guided bilateral pudendal nerve cryoablation in patients with refractory pelvic pain from cancer reporting significant (over 5 units) pain reduction within 24 hours post-treatment [24]. Doubie et al. reported 100% clinical success rate with significant pain reduction lasting for a median of 45 days in patients with dorsal neuropathy pain secondary to tumor invasion [27]. In a retrospective cohort comparison between cryoablation and ethanol for celiac plexus neurolysis in patients with intractable abdominal pain, cryoablation was associated to a lower incidence of diarrhea and fewer gastrointestinal side effects than ablation using ethanol [57].

Cryoanalgesia targets for peripheral neuropathies, apart from pudendal nerve, including among others, occipital, genicular, genitofemoral and lateral femoral cutaneous nerves for the respective neuralgias [28,35,36,39–42]. As a non-opioid technique, cryoablation can provide significant relief in postoperative pain including cases of mastectomy and thoracotomy [32,33]. Application of the technique for phantom limb pain is feasible and safe and may represent a new efficacious therapeutic option for patients with phantom pains related to limb loss [30,31]. Case series of Morton's or sural neuroma and schwannoma report significant efficacy and patient satisfaction rates with no evidence of stump neuroma [44–46]. A recent application of cryoanalgesia includes cryovagotomy in patients with class I or class II obesity, during which percutaneous CT-guided freezing of vagus nerve resulted in 95% of patients reporting decreased appetite following the procedure, with reductions of mean absolute weight and body mass index at all time points, as well as mean quality of life and activity scores improvement [58]. Case reports of other more rare indications for cryoanalgesia, which require further exploration, include

post-herpetic neuralgia and hip adduction spasticity, along with obturator neuralgia [42,59].

In patients with biomechanical syndromes in the spine affecting facet joints of cervical or lumbar levels, cryoablation seems to be associated to less tissue damage, less risk of neuroma or neuritis, and a larger denervation area at the needle tip [3,18,19,37,59]. In a retrospective analysis of 91 patients (117 cryoneurolyses) with lumbar facet joint syndrome, Wolter et al. reported a pain rating reduction from 7.70 before to 3.72 pain units after treatment concluding that the technique can lead to favorable results with sustained pain relief, amelioration of pain-related disability and reduction of depression scores [18]. Similarly, technical reports of cryoanalgesia in cervical facet joints conclude that the technique is feasible, requiring however further studies for verification of the preliminary results [19].

6. Complications

Cryoanalgesia is considered a safe procedure with minimal risk of complications; up-to-date only one event of procedure-related serious complication (myonecrosis and abscess formation) has been reported [54]. In addition, there are no published cases of permanent nerve damage or neuroma, no evidence of permanent changes in nerve function and no risk of de-afferentiation [15,50,55,60]. Mild side effects include local bruising, bleeding and infection [15]. Frostbite, alopecia and depigmentation are possible complications if the ice ball involves the skin [12,15]. Other potential complications include injury to adjacent soft tissue structures including skin necrosis and local vascular thrombotic events for treatment of superficial structures [50]. Non-target ablation must be avoided and partial ablation may result in allodynia or acute exaggeration of pain [12]. Cryoablation offers prolonged analgesic effect, but also prolonged sensory and motor block and the duration of action is often unpredictable, which may not be safe or appropriate in every session [17,32].

Monitoring of ice formation and strategy of needle insertion are of outmost importance in order to avoid complications and damage to surrounding (non-target) structures. Other ancillary techniques for protection and complication avoidance include displacement techniques using fluids (saline), balloons or gases (room air through an antimicrobial filter or carbon dioxide), temperature monitoring by means of a thermosensor placed next to a sensitive structure and neurophysiologic monitoring with somatosensory or motor evoked potentials [61,62].

7. Limitations

The application of cryoablative techniques for the purposes of attenuating nerve signals relies on a specific induction of injury, as above [13,55,63,64]. Interventional cryoneurolysis procedures may be complicated by unwanted sequelae, such as allodynia, neurogenic symptoms, and/or exacerbation of underlying symptoms if the resultant injury falls short of the Sunderland 2 target – resulting in partial ablation. Likewise, exposure to temperatures below target thresholds, or for longer than needed, may result in over-ablation, depending on the device in use. Finally, cryoneurolysis procedures are not dependent on induction of osmotic gradients for cell death as in the case of targeted tumor ablations, and require different protocols than historically used by interventional radiologists for tumors. Careful selection and close monitoring are the keys for a safe and efficacious session. Current procedures are limited by lack of real-time knowledge of in vivo temperatures as a function of time and individual patient characteristics in order to specifically impart the desired lesion and avoid over- or under-ablation. As a result, operators are currently left to modify freeze protocols depending on the target, indication, patient related parameters, and individual experience – an arrangement that may result in variable outcomes [12,14,55,65].

8. Conclusion

Percutaneous cryoanalgesia under imaging guidance can be considered demonstrably effective at treating pain of both neoplastic and non-neoplastic substrate. Imaging guidance and ability to visualize ice ball adds to safety and efficacy. Interventional radiologist should build relations with referring doctors, hospital administrators and local media proposing a non-opioid procedure that can serve as an attractive alternative for pain management.

Human rights

The authors declare that the work described has been carried out in accordance with the Declaration of Helsinki of the World Medical Association revised in 2013 for experiments involving humans.

Informed consent and patient details

The authors declare that this report does not contain any personal information that could lead to the identification of the patients.

Funding

This work did not receive any grant from funding agencies in the public, commercial, or not-for-profit sectors.

Author contributions

All authors attest that they meet the current International Committee of Medical Journal Editors (ICMJE) criteria for Authorship. Dimitrios Filippiadis contributed to the writing – reviewing and editing, data curation, writing – original draft preparation; Evgenia Efthymiou, to the data curation, writing – original draft preparation; Athanasios Tsochatzis, to the writing – original draft preparation, and Alexis Kelekis & David Prologo, to the validation, and supervision.

Disclosure of interest

The authors declare that they have no competing interest.

References

[1] Barat M, Colleter L, Mongiat-Artus P, Jolibois Z, Quero L, Hennequin C, et al. Salvage cryoablation for local recurrence of prostatic cancer after curative therapy. Diagn Interv Imaging 2019;100:679–87.
[2] Matsui Y, Hiraki T, Gobara H, Iguchi T, Tomita K, Uka M, et al. Percutaneous thermal ablation for renal cell carcinoma in patients with Birt–Hogg–Dubé syndrome. Diagn Interv Imaging 2019;100:671–7.
[3] Filippiadis D, Bolotis D, Mazioti A, Tsitskari M, Charalampopoulos G, Vrachliotis T, et al. Percutaneous imaging-guided techniques for the treatment of benign neuropathic pain. Diagn Interv Imaging 2020, http://dx.doi.org/10.1016/j.diii.2020.05.001.
[4] Filippiadis D, Tselikas L, Tsitskari M, Kelekis A, de Baere T, Ryan AG. Percutaneous neurolysis for pain management in oncological patients. Cardiovasc Intervent Radiol 2019;42:791–9.
[5] Lloyd JW, Barnard JD, Glynn CJ. Cryoanalgesia: a new approach to pain relief. Lancet 1976;2:932–4.
[6] Cadaval Gallardo C, Martínez J, Bellía-Munzon G, Nazar M, Sanjurjo D, Toselli L, et al. Thoracoscopic cryoanalgesia: a new strategy for postoperative pain control in minimally invasive pectus excavatum repair. Cir Pediatr 2020;33:11–5.
[7] Tanaka A, Al-Rstum Z, Leonard SD, Gardiner BD, Yazij I, Sandhu HK, et al. Intraoperative intercostal nerve cryoanalgesia improves pain control after descending and thoracoabdominal aortic aneurysm repairs. Ann Thorac Surg 2020;109:249–54.

[8] Harbaugh CM, Johnson KN, Kein CE, Jarboe MD, Hirschl RB, Geiger JD, et al. Comparing outcomes with thoracic epidural and intercostal nerve cryoablation after Nuss procedure. J Surg Res 2018;231:217–23.
[9] Sujka J, Benedict LA, Fraser JD, Aguayo P, Millspaugh DL, St Peter SD. Outcomes using cryoablation for postoperative pain control in children following minimally invasive pectus excavatum repair. J Laparoendosc Adv Surg Tech A 2018;28:1383–6.
[10] Dekonenko C, Dorman RM, Duran Y, Juang D, Aguayo P, Fraser JD, et al. Postoperative pain control modalities for pectus excavatum repair: a prospective observational study of cryoablation compared to results of a randomized trial of epidural vs. patient-controlled analgesia. J Pediatr Surg 2020;55:1444–7.
[11] Graves CE, Moyer J, Zobel MJ, Mora R, Smith D, O'Day M, et al. Intraoperative intercostal nerve cryoablation during the Nuss procedure reduces length of stay and opioid requirement: a randomized clinical trial. J Pediatr Surg 2019;54:2250–6.
[12] Bittman RW, Behbahani K, Gonzalez F, Prologo JD. Interventional cryoneurolysis: what is the same, what is different, what is new? Semin Intervent Radiol 2019;36:374–80.
[13] Trescot AM. Cryoanalgesia in interventional pain management. Pain Physician 2003;6:345–60.
[14] Sunderland S. A classification of peripheral nerve injuries producing loss of function. Brain 1951;74:491–516.
[15] Gabriel RA, Finneran JJ, Asokan D, Trescot AM, Sandhu NS, Ilfeld BM. Ultrasound-guided percutaneous cryoneurolysis for acute pain management: a case report. A A Case Rep 2017;9:129–32.
[16] Myers RR, Heckman HM, Powell HC. Axonal viability and the persistence of thermal hyperalgesia after partial freeze lesions of nerve. J Neurol Sci 1996;139:28–38.
[17] Ilfeld BM, Gabriel RA, Trescot AM. Ultrasound-guided percutaneous cryoneurolysis providing postoperative analgesia lasting many weeks following a single administration: a replacement for continuous peripheral nerve blocks? A case report. Korean J Anesthesiol 2017;70:567–70.
[18] Wolter T, Deininger M, Hubbe U, Mohadjer M, Knoeller S. Cryoneurolysis for zygapophyseal joint pain: a retrospective analysis of 117 interventions. Acta Neurochir 2011;153:1011–9.
[19] Wolter T, Kleinmann B, Knoeller S. Cryoneurolysis for the treatment of cervical facet joint syndrome: a technical note. J Pain Res 2018;11:1165–9.
[20] Bittman RW, Peters GL, Newsome JM, Friedberg EB, Mitchell JW, Knight JM, et al. Percutaneous image-guided cryoneurolysis. AJR Am J Roentgenol 2018;210:454–65.
[21] Cornelis FH, Monard E, Moulin MA, Vignaud E, Laveissiere F, Ben Ammar M, et al. Sedation and analgesia in interventional radiology: where do we stand, where are we heading and why does it matter? Diagn Interv Imaging 2019;100:753–62.
[22] Bhattacharji P, Moore W. Application of real-time 3D navigation system in CT-guided percutaneous interventional procedures: a feasibility study. Radiol Res Pract 2017;2017:3151694.
[23] Mokry A, Willmitzer F, Hostettler R, Richter H, Kircher P, Kneissl S, et al. Evaluation of a novel, patient-mounted system for CT-guided needle navigation – an ex vivo study. Neuroradiology 2019;61:55–61.
[24] Prologo JD, Manyapu S, Bercu ZL, Mittal A, Mitchell JW. Percutaneous CT-guided cryoablation of the bilateral pudendal nerves for palliation of intractable pain related to pelvic neoplasms. Am J Hosp Palliat Care 2020;37:619–23.
[25] Yarmohammadi H, Nakamoto DA, Azar N, Hayek SM, Haaga JR. Percutaneous computed tomography guided cryoablation of the celiac plexus as an alternative treatment for intractable pain caused by pancreatic cancer. J Cancer Res Ther 2011;7:481–3.
[26] Cornman-Homonoff J, Formenti SC, Chachoua A, Madoff DC. Percutaneous cryoablation for the management of chronic pain secondary to locally recurrent rectal cancer with bowel and nerve root involvement. J Vasc Interv Radiol 2018;29:1296–8.
[27] Daubié S, Pilleul F, Thivolet A, Kalenderian AC, Cuinet M, Ricoeur A, et al. Cryoneurolysis in patients with dorsal neuropathic pain secondary to tumor invasion. J Vasc Interv Radiol 2020;31:917–24.
[28] Kim CH, Hu W, Gao J, Dragan K, Whealton T, Julian C. Cryoablation for the treatment of occipital neuralgia. Pain Physician 2015;18:E363–8.
[29] Kastler A, Onana Y, Comte A, Attyé A, Lajoie JL, Kastler B. A simplified CT-guided approach for greater occipital nerve infiltration in the management of occipital neuralgia. Eur Radiol 2015;25:2512–8.
[30] Prologo JD, Gilliland CA, Miller M, Harkey P, Knight J, Kies D, et al. Percutaneous image-guided cryoablation for the treatment of phantom limb pain in amputees: a pilot study. J Vasc Interv Radiol 2017;28:24e4–34e4.
[31] Gabriel RA, Finneran JJt, Trescot AM, Ilfeld BM. Ultrasound-guided percutaneous cryoneurolysis for postoperative analgesia after limb amputation: a case series. A A Pract 2019;12:231–4.
[32] Gabriel RA, Finneran JJ, Swisher MW, Said ET, Sztain JF, Khatibi B, et al. Ultrasound-guided percutaneous intercostal cryoanalgesia for multiple weeks of analgesia following mastectomy: a case series. Korean J Anesthesiol 2020;73:163–8.
[33] Koethe Y, Mannes AJ, Wood BJ. Image-guided nerve cryoablation for post-thoracotomy pain syndrome. Cardiovasc Intervent Radiol 2014;37:843–6.
[34] Byas-Smith MG, Gulati A. Ultrasound-guided intercostal nerve cryoablation. Anesth Analg 2006;103:1033–5.
[35] Dasa V, Lensing G, Parsons M, Harris J, Volaufova J, Bliss R. Percutaneous freezing of sensory nerves prior to total knee arthroplasty. Knee 2016;23:523–8.
[36] Radnovich R, Scott D, Patel AT, Olson R, Dasa V, Segal N, et al. Cryoneurolysis to treat the pain and symptoms of knee osteoarthritis: a multicenter, randomized, double blind, sham-controlled trial. Osteoarthritis Cartilage 2017;25:1247–56.
[37] Birkenmaier C, Veihelmann A, Trouillier H, Hausdorf J, Devens C, Wegener B, et al. Percutaneous cryodenervation of lumbar facet joints: a prospective clinical trial. Int Orthop 2007;31:525–30.
[38] Staender M, Maerz U, Tonn JC, Steude U. Computerized tomography-guided kryorhizotomy in 76 patients with lumbar facet joint syndrome. J Neurosurg Spine 2005;3:444–9.
[39] Campos NA, Chiles JH, Plunkett AR. Ultrasound-guided cryoablation of genitofemoral nerve for chronic inguinal pain. Pain Physician 2009;12:997–1000.
[40] Calixte N, Kartal IG, Tojuola B, Gudeloglu A, Etafy M, Brahmbhatt JV, et al. Salvage ultrasound-guided targeted cryoablation of the perispermatic cord for persistent chronic scrotal content pain after microsurgical denervation of the spermatic cord. Urology 2019;130:181–5.
[41] Finneran JJ, Swisher MW, Gabriel RA, Fiallo A, Hamilton JR, Lee JG, et al. Ultrasound-guided lateral femoral cutaneous nerve cryoneurolysis for analgesia in patients with burns. J Burn Care Res 2020;41:224–7.
[42] Weber G, Saad K, Awad M, Wong TH. Case report of cryoneurolysis for the treatment of refractory intercostobrachial neuralgia with post-herpetic neuralgia. Local Reg Anesth 2019;12:103–7.
[43] Prologo JD, Lin RC, Williams R, Corn D. Percutaneous CT-guided cryoablation for the treatment of refractory pudendal neuralgia. Skeletal Radiol 2015;44:709–14.
[44] Cazzato RL, Garnon J, Ramamurthy N, Tsoumakidou G, Caudrelier J, Thenint MA, et al. Percutaneous MR-guided cryoablation of Morton's neuroma: rationale and technical details after the first 20 patients. Cardiovasc Intervent Radiol 2016;39:1491–8.
[45] Mavrovi E, Vaz G, Thiesse P, Richioud B. Percutaneous cryoablation: a promising treatment for peripheral schwannoma. Diagn Interv Imaging 2016;97:923–5.
[46] Rhame EE, Debonet AF, Simopoulos TT. Ultrasonographic guidance and characterization of cryoanalgesic lesions in treating a case of refractory sural neuroma. Case Rep Anesthesiol 2011;2011:691478.
[47] Martell B, Jesse MK, Lowry P. CT-guided cryoablation of a peripheral nerve sheath tumor. J Vasc Interv Radiol 2016;27:148–50.
[48] Ramsook RR, Spinner D. Ultrasound-guided cryoablation of a traumatic hip disarticulation neuroma. Pain Pract 2017;17:941–4.
[49] Yoon JH, Grechushkin V, Chaudhry A, Bhattacharji P, Durkin B, Moore W. Cryoneurolysis in patients with refractory chronic peripheral neuropathic pain. J Vasc Interv Radiol 2016;27:239–43.
[50] Djebbar S, Rossi IM, Adler RS. Ultrasound-guided cryoanalgesia of peripheral nerve lesions. Semin Musculoskelet Radiol 2016;20:461–71.
[51] Kim PS, Ferrante FM. Cryoanalgesia: a novel treatment for hip adductor spasticity and obturator neuralgia. Anesthesiology 1998;89:534–6.
[52] Joshi DH, Thawait GK, Del Grande F, Fritz J. MRI-guided cryoablation of the posterior femoral cutaneous nerve for the treatment of neuropathy-mediated sitting pain. Skeletal Radiol 2017;46:983–7.
[53] McLean BC, Nguyen CD, Newman DP. Cryoablation of the infrapatellar branch of the saphenous nerve identified by non-invasive peripheral nerve stimulator for the treatment of non-surgical anterior knee pain: a case series and review of the literature. Cureus 2020;12:e8747.
[54] Cahani D, Chacko J, Hahn B. Myonecrosis: a rare complication of cryoneurolysis. J Emerg Med 2019;57:e73–6.
[55] Shah SB, Bremner S, Esparza M, Dorn S, Orozco E, Haghshenas C, et al. Does cryoneurolysis result in persistent motor deficits? A controlled study using a rat peroneal nerve injury model. Reg Anesth Pain Med 2020;45:287–92.
[56] Bärlocher CB, Krauss JK, Seiler RW. Kryorhizotomy: an alternative technique for lumbar medial branch rhizotomy in lumbar facet syndrome. JNS 2003;98:14–20.
[57] Behbahani K, Chary A, Patel S, Mitchell JW, Fleishon H, Prologo JD. Percutaneous CT-guided cryoablation of the celiac plexus: a retrospective cohort comparison with ethanol. J Vasc Interv Radiol 2020;31:1216–20.
[58] Prologo JD, Lin E, Horesh-Bergquist S, Knight J, Matta H, Brummer M, et al. Percutaneous CT-guided cryovagotomy in patients with class I or class II obesity: a pilot trial. Obesity 2019;27:1255–65.
[59] Perolat R, Kastler A, Nicot B, Pellat JM, Tahon F, Attye A, et al. Facet joint syndrome: from diagnosis to interventional management. Insights Imaging 2018;9:773–89.
[60] Ramirez M, Ravichandran S, Ronald L, Pabon-Ramos WM, Smith TP, Kim CY, et al. Recognition and management of dermatologic complications from interventional radiology procedures. Diagn Interv Imaging 2019;100:659–70.
[61] Kurup AN, Schmit GD, Morris JM, Atwell TD, Schmitz JJ, Weisbrod AJ, et al. Avoiding complications in bone and soft tissue ablation. Cardiovasc Intervent Radiol 2017;40:166–76.
[62] Yoon JT, Nesbitt J, Raynor BL, Roth M, Zertan CC, Jennings JW. Utility of motor and somatosensory evoked potentials for neural thermoprotection in ablations of musculoskeletal tumors. J Vasc Interv Radiol 2020;31:903–11.
[63] Prologo JD, Johnson C, Hawkins CM, Singer A, Manyapu SR, Chang-Yeon K, et al. Natural history of mixed and motor nerve cryoablation in humans – a cohort analysis. J Vasc Interv Radiol 2020;31:912e1–6e1.
[64] BM Preciado J, Trescot AM. Novel cryoneurolysis device for the treatment of sensory and motor peripheral nerves. Expert Rev Med Devices 2016;13:713–25.
[65] Prologo JD. Percutaneous CT-guided cryovagotomy. Tech Vasc Interv Radiol 2020;23:100660.